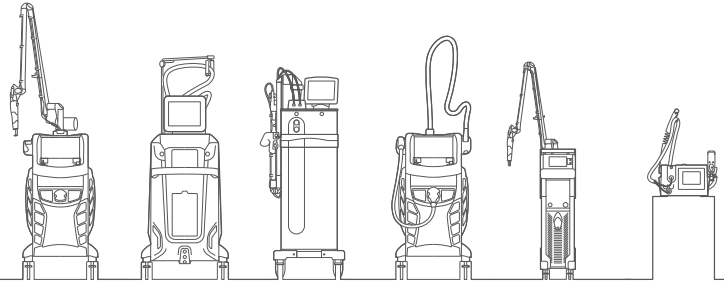


# Reference List



Ying-Xiu Dai, Ying-Yen Chuang, Po-Yu Chen, and Chih-Chiang Chen.  
Efficacy and safety of ablative resurfacing with a high-energy 1,064 nm Nd:YAG picosecond-domain laser for the treatment of facial acne scars in Asians.  
*Lasers Surg. Med.* © 2019 Wiley Periodicals, Inc. (wileyonlinelibrary.com).  
DOI 10.1002/lsm.23151

Guida S, Giovanni P, Bencini PL.  
Picosecond laser treatment of atrophic and hypertrophic surgical scars: In vivo monitoring of results by means of 3D imaging and reflectance confocal microscopy.  
*Skin Res Technol.* 2019;00:1–7. <https://doi.org/10.1111/srt.12755>

Haider Al-Sabak Muhsin A. Al-Dhalimi Wid Abbas Ali.  
Treatment Of Verruca Vulgaris with Long Pulsed Nd:YAG Laser 1064 nm In Iraqi Patients.  
*KUFA JOURNAL FOR NURSING SCIENCES.VOL.9 No. 1 / 2019*

Ploypailin Tantrapornpong, Punyaphat Sirithanabadeekul.  
Efficacy and Safety of Using a Fractional Picosecond 1064-nm Laser for Treatment of Atrophic Acne Scars in Asian Skin Types.  
*TJPS Vol.42 (Supplement Issue) 2018*

S. Guida, P.L. Bencini, G. Pellacani.  
Picosecond laser for atrophic surgical scars treatment: in vivo monitoring of results by means of reflectance confocal microscopy.  
Letter to the editor. *J EADV* 2018. DOI: 10.1111/jdv.15289

Nark-Kyoung Rho, Sung Tae Chung.  
Treatment of a Full-thickness Laceration Scar on the Forehead Using a 1,064-nm Fractional Picosecond Laser and Polynucleotide Gel Injection.  
*Med Laser* 2018;7(2):88-90. <https://doi.org/10.25289/ML.2018.7.2.88>

Variya Laothaworn & Premjit Juntongjin (2018):  
Topical 3% tranexamic acid enhances the efficacy of 1064-nm Q-switched neodymium-doped yttrium aluminum garnet laser in the treatment of melasma.  
*Journal of Cosmetic and Laser Therapy*, DOI:10.1080/14764172.2018.1427869

Murtadha Hashim Al-janabi, Noor Taha Ismaeel Ali, Karrar Deiaa Mohamed Al-Sabti, Muhsin A. Al-Dhalimi & Sahib Neamh Abdul Wahid (2017).  
A new imaging technique for assessment of the effectiveness of long pulse Nd:YAG 532 nm laser in treatment of facial port wine stain.  
*Journal of Cosmetic and Laser Therapy*, 19:7, 418-421, DOI:10.1080/14764172.2017.1341985

K. Greveling, E.P. Prens, N. ten Bosch and M. B. van Doorn.  
Comparison of lidocaine/tetracaine cream and lidocaine/prilocaine cream for local anaesthesia during laser treatment of acne keloidalis nuchae and tattoo removal: results of two randomized controlled trials.  
*British Journal of Dermatology* (2017) 176, pp81–86. DOI 10.1111/bjd.14848

Barakat MT, Moftah NH, El Khayyat MAM, and Abdelhakim ZA.  
Significant reduction of inflammation and sebaceous glands size in acne vulgaris lesions after intense pulsed light treatment.  
*Dermatologic Therapy* 2017;30: e12418. doi:10.1111/dth.12418.

El-Domyati M, Wael H, Noha M, Hamza A, Selwet M.  
Hair follicle changes following intense pulsed light axillary hair reduction: histometrical, histological and immunohistochemical evaluation.  
*Archives of Dermatological Research* (2017); 309(3):191– 200

Al-Dhalimi MA, Al-Janabi MH.  
Split lesion randomized comparative study between long pulsed Nd:YAG laser 532 and 1,064 nm in treatment of facial port-wine stain.  
*Lasers Surg Med* 2016;48:852–8.

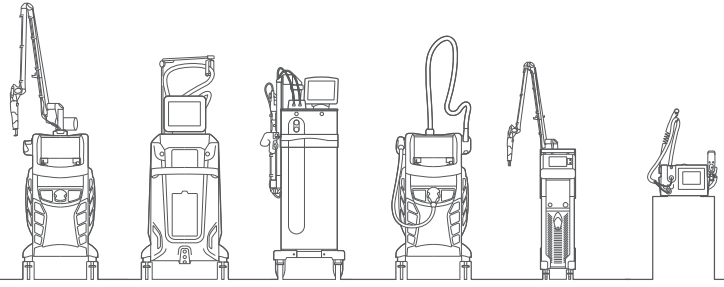
Paolo Mezzana, Maurizio Valeriani & Roberto Valeriani (2016):  
Combined fractional resurfacing (10600nm/1540nm): Tridimensional imaging evaluation of a new device for skin rejuvenation  
*Journal of Cosmetic and Laser Therapy*, DOI:10.1080/14764172.2016.1202417

Paradisi A, Ricci F, Sbrano P.  
"Drug-resistant granuloma faciale": treatment with carbon dioxide-GaAs laser.  
*Dermatol Ther* 2016; 29: 317–319.

Maluki AH, Al-Sabak HA (2015)  
Split Face Comparative Study of using Fractional Erbium: Glass 1540 Nanometer and Nd: YAG Q-Switched 1064 Nanometer Laser Systems in the Treatment of Melasma.  
*J Dermatol Res Ther* 1:002

Mohammad Radmanesh & Zohreh Rafiei (2015)  
Combination of CO2 and Q-switched Nd:YAG lasers is more effective than Q-switched Nd:YAG laser alone for eyebrow tattoo removal  
*Journal of Cosmetic and Laser Therapy*, 17:2, 65-68, DOI:10.3109/14764172.2014.988724

# Reference List



Muhsin Al-Dhalimi & Akeel Jaber (2015)

Treatment of atrophic facial acne scars with fractional Er:Yag laser  
Journal of Cosmetic and Laser Therapy, 17:4, 184-188, DOI:  
10.3109/14764172.2015.1007067

Leclère FM, Moreno-Moraga J, Alcolea JM, Casoli V, Mordon SR, Vogt PM, Trelles MA (2014)

Laser assisted lipolysis for neck and submental remodeling in Rohrich type I to III aging neck: a prospective study in 30 patients.  
J Cosmet Laser Ther 16(6):284–289

Muhsin A. Al-Dhalimi & Ali A. Abo Nasyria (2013)

A comparative study of the effectiveness of intense pulsed light wavelengths (650 nm vs 590 nm) in the treatment of striae distensae.  
Journal of Cosmetic and Laser Therapy, 15:3, 120-125, DOI:  
10.3109/14764172.2012.748200

Al-Dhalimi MA, Abo Nasyria AA.

A comparative study of the effectiveness of intense pulsed light wavelengths (650 nm vs 590 nm) in the treatment of striae distensae.  
J Cosmet Laser Ther 2013;15:120-5.

Trelles MA, Mordon SR, Bonanad E, Moreno Moraga J, Heckmann A, Unglaub F, Betrouni N, Leclère FM (2013) Laser-assisted lipolysis in the treatment of gynecomastia: a prospective study in 28 patients. Lasers Med Sci 28:375–382

Kassab AN, El Kharbotly A.

Management of ear lobule keloids using 980-nm diode laser.  
Eur Arch Otorhinolaryngol. 2012;269(2):419–423.

Leclère FM, Trelles M, Moreno-Moraga J, Servell P, Unglaub F, Mordon SR (2012)

980-nm laser lipolysis (LAL): About 674 procedures in 359 patients.  
J Cosmet Laser Ther 14:67–73

Bouzari N, Tabatabai H, Abbasi Z, et al.

Laser hair removal: comparison of long-pulsed Nd:YAG, long-pulsed alexandrite, and long-pulsed diode lasers.  
Dermatol Surg 2004;30:498-502.